



PATIENT

Magnum Ashton-Magnuson

SPECIES

Feline

BREED

DMH

SEX

Male Neutered

AGE

13 years

WEIGHT

13.13lbs

INTERPRETED BY

Maggie Machen
Lamy, DVM
DACVIM (Cardiology)

IMAGING PERFORMED BY

Pamela Harrigan,
RDMS

HOSPITAL NAME

Mass Veterinary Services

REFERRING VET

Dr. Masloski

INVOICE

32467

DATE

8/22/23

PRESENTING CLINICAL SIGNS

History: Magnum was noted to have a gallop rhythm in June. A thyroid level at that time was normal. He is presently doing well with a good appetite and normal activity level. He does open mouth breathe on car rides. On exam: arrhythmia, no murmurs noted, PSS, lung fields clear, compressible thorax, mm pink, moist, CRT < 2. BP: 130mmHg. Current medications: gabapentin transdermal prior to vet visits *Sedated with Propofol for study.

ECHOCARDIOGRAM FINDINGS

2D, m-mode, color flow and Doppler imaging is available.

Left ventricle: The LV diameter is normal with adequate myocardial function. The LV wall dimensions are normal. There is mild fibrosis of the endocardium. The endocardium appears mildly remodeled. The papillary muscles appear hyperechoic and normal in dimension. False tendon.

Left atrium: The left atrium is normal. No obvious smoke or thrombi seen.

Mitral valve: The mitral valve is normal in structure and mobility. No obvious systolic anterior motion is seen. No MR.

Aortic valve/aorta: The aortic valve is normal in morphology and mobility. Normal aortic outflow velocity; laminar flow. No aortic insufficiency.

Right ventricle: Normal right ventricular diameter and morphology indicating no overt evidence of pulmonary arterial hypertension.

Right atrium: The right atrium is normal in dimension.

Tricuspid valve: The tricuspid valve appears normal with trace/mild tricuspid regurgitation. Normal velocity.

Pulmonic valve/pulmonary artery: The pulmonic valve is normal in morphology and mobility. No pulmonic insufficiency. Normal RVOT velocity; laminar flow.

Pericardium/other: No pericardial or pleural effusion noted. No obvious cardiac masses.

Heart rhythm: ECG reveals a sinus rhythm with an average HR of 188bpm.

2-Dimensional Measurements

Ao diam (cm)	1.1
LA diam (cm)	1.2
LA:Ao (Swe)	1.0
IVS thickness (cm)	0.45
LVID diastole (cm)	1.46
PW thickness (cm)	0.38
LVID systole (cm)	0.9
FS (%)	40

Doppler Measurements

PV Vmax (m/s)	0.5
AoV Vmax (m/s)	0.7
MR Vmax (m/s)	NA
TR Vmax (m/s)	1.6
TR PG (mmHg)	10

INTERPRETATION OF THE FINDINGS

Overtly normal geriatric cardiac structure and function are identified. Mild remodeling fibrosis of the left ventricular wall is noted, which is likely a normal age-related variant. No significant valve leaks are noted, and flow through the great vessels is normal in velocity. No significant pathology is appreciated to explain the gallop, which likely suggests this is a normal age-related finding due to diastolic stiffening.

Prognosis is open.



PATIENT

Magnum Ashton-Magnuson

SPECIES

Feline

BREED

DMH

SEX

Male Neutered

AGE

13 years

WEIGHT

13.13lbs

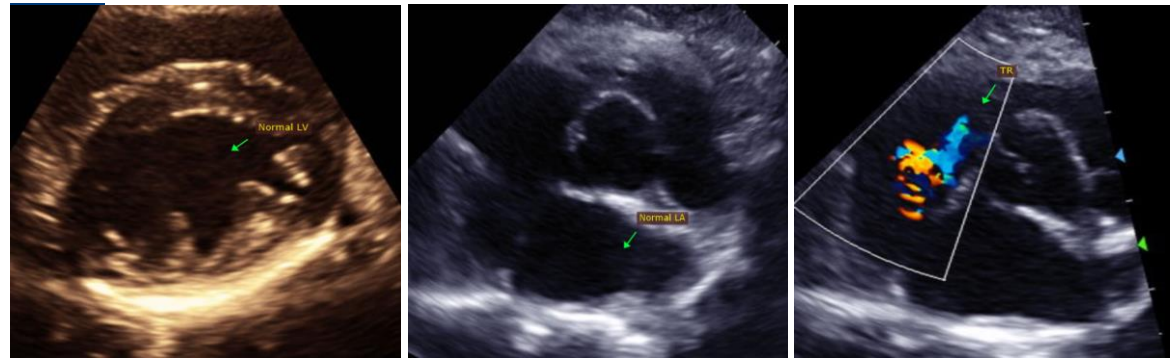
RECOMMENDATIONS

- Given these findings, no medications are indicated.
- No cardiac contraindication for general anesthesia. Should fluid or steroid therapy be indicated in the future, any cat should be monitored for intolerance (changes in RR/RE).
- Monitor at home for signs of cardiac compromise, including respiratory changes and/or signs of a blood clot event (paralysis, neurologic changes).

PLAN

- Recommend recheck echocardiogram in 1 year to screen for any progressive issues.

IMAGES



The information and recommendations provided are based on the images presented by the referring veterinarian. No evaluation can be communicated regarding pathology that was not visible in the image/video clips provided.

Thank you for this referral. This report was generated using transcription software, and minor dictation errors may be present. If the clinical or image interpretation does not parallel your findings or if I can be of any further assistance, please contact me.

INTERPRETED BY

Maggie Machen Lamy, DVM
DACVIM (Cardiology)

Maggie Machen Lamy, DVM
Diplomate of the American College of Veterinary Internal Medicine (Cardiology)
info@sonopath.com

Echocardiogram performed by: Pamela Harrigan, RDCS
Pet Animal Ultrasound Service (4paus.com)

HOSPITAL NAME

Mass Veterinary Services

REFERRING VET

Dr. Masloski

INVOICE

32467

DATE

8/22/23